



PRESENTING CLINICAL SIGNS

History: Cardiac screening exam. No murmur.

DATE

5/11/23

ECHOCARDIOGRAPHIC FINDINGS

2D, M-mode, and Doppler study.

PERFORMED BY:

Shari Reffi, CVT

Left atrial size is normal. The mitral valve is normal. Left ventricular wall thickness is normal. Left ventricular internal dimensions are normal. Left ventricular systolic function is hyperdynamic. The aorta and aortic valve are normal. Right atrial and right ventricular dimensions are normal. The tricuspid valve is normal. The pulmonary artery and pulmonic valve are normal. No pericardial effusion or cardiac masses are seen.

INTERPRETED BY

Keith Blass, DVM,
MS, DACVIM
(Cardiology)

LA/Ao - 1.20
IVSd - 4.0 mm
LVPWd - 3.9 mm
LVIDd - 15.2 mm
LVIDs - 6.8 mm
FS - 55%
LVOT - 1.00 m/s
RVOT - 0.82 m/s

PATIENT

Emerald Coe

ASSESSMENT/RECOMMENDATIONS

Normal echocardiogram

SPECIES

Feline

This examination demonstrates no evidence of structural heart disease.

No therapy is recommended based on this exam.

BREED

Sphynx

A recheck echocardiogram is recommended if new physical exam and/or clinical abnormalities suggestive of the presence of cardiac dysfunction develop.

SEX

FS

AGE

5 y

WEIGHT

7.38 lb

HOSPITAL NAME

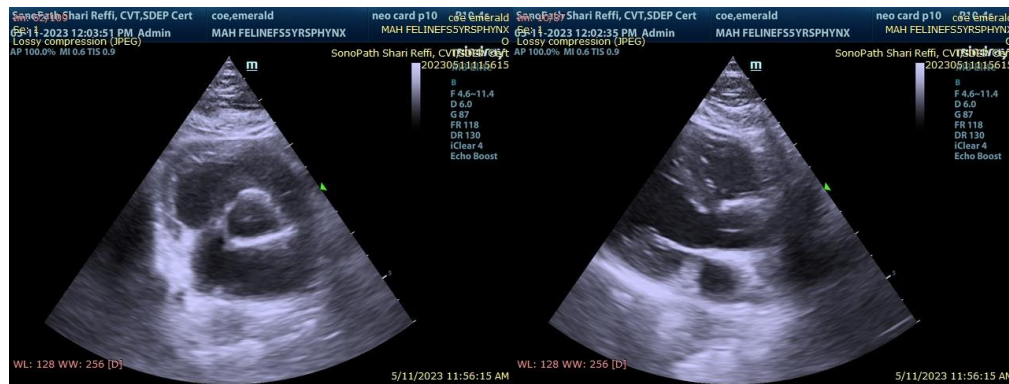
Milford AH

The information and recommendations provided are based on the images presented by the referring veterinarian. No evaluation can be communicated regarding pathology that was not visible in the image/video clips provided.

REFERRING VET

Dr. Grasso

Thank you for this referral. If the clinical or image interpretation does not parallel your findings or if I can be of any further assistance please contact me.





Keith Blass, DVM, MS, DACVIM (Cardiology)

KeithBlass@gmail.com

631-804-5754

DATE

5/11/23

PERFORMED BY:

Shari Reffi, CVT

INTERPRETED BY

Keith Blass, DVM,
MS, DACVIM
(Cardiology)

PATIENT

Emerald Coe

SPECIES

Feline

BREED

Sphynx

SEX

FS

AGE

5 y

WEIGHT

7.38 lb

HOSPITAL NAME

Milford AH

REFERRING VET

Dr. Grasso